



GUIDELINE

Malrotation / Volvulus of the Intestines

Scope (Staff):	Nursing and Medical Staff
Scope (Area):	NICU KEMH, NICU PCH, NETS WA

Child Safe Organisation Statement of Commitment

CAHS commits to being a child safe organisation by applying the National Principles for Child Safe Organisations. This is a commitment to a strong culture supported by robust policies and procedures to reduce the likelihood of harm to children and young people.

This document should be read in conjunction with this [disclaimer](#)

Background

Malrotation is a congenital condition of the gut which occurs as a result of failure of fixation of bowel inside the abdominal cavity during fetal development. The malrotated gut is prone to volvulus resulting in bowel obstruction and gangrene secondary to occlusion of the branches of the mesenteric artery. This is serious and potentially fatal sequelae. Intestinal obstruction due to malrotation can also result because of congenital fibrous (Ladd's) bands that can partially block and presents with intermittent bilious vomits in an apparently well looking neonate.

30% of infants with malrotation present in the first three to seven days of life and 80% present in the first month of life, mostly in the first week.

Key points

- Any **bilious vomiting or aspirates** is an important sign of malrotation and must be promptly investigated. See [Feed Intolerance Guideline](#)
- Normal abdominal examination, AXR, lactate levels, blood pressure, urine output, blood gases do not rule out early intestinal gangrene secondary to malrotation/volvulus.
- Gold standard for investigating a suspected malrotation is Upper GI contrast study.
- Ultrasound of the abdomen is NOT a substitute for upper GI contrast, but can be used as the initial line of investigation in critically ill very preterm infants, who are too unstable to undergo contrast study. Close collaboration with the surgeons and radiologists is essential in such situations.

Clinical Presentation

- Bilious vomiting must be promptly investigated even if the abdomen is soft and non-tender.
- Bilious aspirates in premature infants <32 week can be due to dysmotility and be more difficult to interpret and definitively investigate in a small sick baby; Consultant staff must always be aware of the presence of bile stained aspirates in babies >32 weeks. Preterm infants with persistent bilious aspirates should raise the suspicion of malrotation necessitating investigation.
- Presence of distended tender/non tender abdomen in any neonate should prompt an investigation to rule out malrotation/volvulus irrespective of the presence or absence of vomiting.
- Presence of chylous fluid in an inguinal hernia sac during inguinal hernia repair should alert the surgeon and the neonatologists to the possibility of associated malrotation. See NETS WA Guidelines, [Surgical Conditions](#)
- Bloody stools and pallor.

Investigations and Management

Clinical judgement and prompt discussion with the surgeons is essential in an unwell infant with a distended abdomen. Once a diagnosis of malrotation and or volvulus is confirmed, the infant should be reviewed by the surgeon as soon as possible with a view to urgent laparotomy.

- Keep baby nil by mouth.
- Insert a large bore naso/orogastric tube; keep the tube on open drainage.
- Collect blood for sepsis screen, blood gas, glucose and blood group ([Sepsis: Neonatal](#))
- Start IV Fluids and IV antibiotics ([Amoxicillin/Benzylpenicillin](#), [Gentamicin](#) and [Metronidazole](#)).
- Assess if resuscitation fluids are required.
- Monitor urine output.

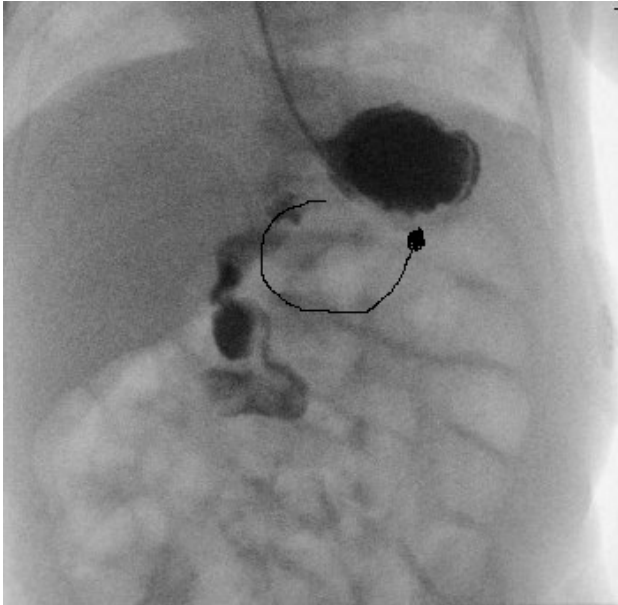
Radiological Investigations

Plain X-ray of the abdomen is often non-specific. Dilatation of multiple loops of bowel on plain X-ray can signify volvulus with gut ischemia. Obtain both antero-posterior and lateral decubitus view of abdomen to rule out any gas under diaphragm.

The gold standard imaging test for diagnosing malrotation is an **upper GI contrast study** which shows an abnormal duodenum and duodenojejunal (DJ) flexure position. This is an emergency investigation and should not be deferred for any reason, even in otherwise well infants. The normal position of the DJ flexure is to the left of the spine

and at the same level or higher than the duodenal bulb. Liaise with on call radiological consultant/registrar for arranging upper GI contrast study.

Although ultrasound of the abdomen is NOT a substitute for upper GI contrast, it can be useful in a critically ill preterm infant, who are too unstable to undergo contrast study. The ultrasound can show the orientation of the superior mesenteric vessels or the presence of a volved, ischemic mass.



Contrast exits stomach and descends instead of following the path drawn.

Surgical and Post-Operative Management

Ladd's procedure.

Post-operative management includes analgesia (morphine), moderate maintenance fluid restriction (SIADH risk), monitor intake-output chart. Check the position of endotracheal tube with a chest X-ray if the infant returns to the NICU with a new ETT. Every infant should have a blood gas, electrolytes and FBC (and coagulation profile if indicated) soon after return to the NICU. Parenteral nutrition may be necessary for an extended period of time if a long segment of ischemic gut has been removed.

- Continue antibiotics.
- Refer to [Post Operative Care](#) guideline.
- Check the surgeon's orders on the Operation Theatre Notes.
- Discuss with the neonatal consultant.
- NBM until decision to feed is made by the surgeon.

Related CAHS internal policies, procedures and guidelines

[Feed Intolerance Guideline](#) (Neonatal set)

[Post Operative Care](#) (Neonatal set)


[Post Operative Handover](#) (Neonatal set)

[Surgical Conditions](#) (NETS WA set)

References and related external legislation, policies, and guidelines

1. Burge DM. The management of bilious vomiting in the neonate. *Early Human Development* 2016;102:41-45.
2. M. Drewett, N. Johal, C. Keys, J. Hall, D. Burge, The burden of excluding malrotation in term neonates with bile stained vomiting, *Pediatr. Surg. Int.* 2016 May; 32 (5) : 483–486.
3. S.C. Blackburn, Term newborns with bilious vomiting: when should they see a surgeon and how soon? *Arch. Dis. Child.* 2015 Jan; 100 (1): 1–2.
4. Shalaby MS, Kuti K, Walker G. Intestinal malrotation and volvulus in infants and children. *BMJ* 2013; 347: f6949.
5. Zarroug AE, Srinivasan SK, Wulkan ML. Incidental chylous fluid during hernia repair may be a harbinger of malrotation. *J Pediatr Surg.* 2010 Jan;45(1):E17-8.
6. Applegate KE. Evidence-based diagnosis of malrotation and volvulus. *Pediatr Radiol.* 2009 Apr;39 Suppl 2:S161-3.
7. Danse EM, Kartheuser A, Paterson HM, Laterre PF. Color Doppler sonography of small bowel wall changes in 21 consecutive cases of acute mesenteric ischemia. *JBR-BTR.* 2009 Jul-Aug;92(4):202-6.
8. Kumar N, Curry JI. Bile-stained vomiting in the infant: green is not good! *Arch Dis Child Educ Pract Ed.* 2008 Jun;93(3):84-6.
9. Williams H. Green for danger! Intestinal malrotation and volvulus. *Arch Dis Child Educ Pract Ed.* 2007 Jun;92(3):ep87-91.
10. Applegate KE, Anderson JM, Klatte EC. Intestinal malrotation in children: a problem-solving approach to the upper gastrointestinal series. *Radiographics.* 2006 Sep-Oct;26(5):1485-500.
11. Millar AJ, Rode H, Cywes S. Malrotation and volvulus in infancy and childhood. *Semin Pediatr Surg.* 2003 Nov;12(4):229-36.
12. Chao HC, Kong MS, Chen JY, Lin SJ, Lin JN. Sonographic features related to volvulus in neonatal intestinal malrotation. *J Ultrasound Med.* 2000 Jun;19(6):371-6.
13. <https://starship.org.nz/guidelines/surgery-management-of-intestinal-malrotation-in-the-neonate/>

This document can be made available in alternative formats on request.

Document Owner:	Neonatology		
Reviewer / Team:	Neonatology		
Date First Issued:	June 2010	Last Reviewed:	November 2021
Amendment Dates:	22/12/21 - hyperlinks	Next Review Date:	23 rd November 2024
Approved by:	Neonatal Coordinating Group	Date:	23 rd November 2021
Endorsed by:	Neonatal Coordinating Group	Date:	
Standards Applicable:	NSQHS Standards:  Child Safe Standards: 1,10		

Printed or personally saved electronic copies of this document are considered uncontrolled



Healthy kids, healthy communities

Compassion Excellence Collaboration Accountability Equity Respect

Neonatology | Community Health | Mental Health | Perth Children's Hospital