



GUIDELINE

Sacral Dimples or Pits

Scope (Staff):	Midwifery, Nursing and Medical Staff
Scope (Area):	NICU KEMH, NICU PCH, NETS WA, KEMH Postnatal Wards

Child Safe Organisation Statement of Commitment

CAHS commits to being a child safe organisation by applying the National Principles for Child Safe Organisations. This is a commitment to a strong culture supported by robust policies and procedures to reduce the likelihood of harm to children and young people.

This document should be read in conjunction with this [disclaimer](#)

Aim

To facilitate appropriate investigation and management of sacral dimples and pits in neonates.

Risk

- Simple sacral dimples and pits are common in neonates and seldom associated with spinal dysraphism.
- Unnecessary investigation increases parental anxiety, may prolong hospital stay following delivery and increases medical costs.

Background

A simple sacral dimple, defined as a midline dimple, within the gluteal cleft and without associated cutaneous abnormalities, is a common finding and considered to be a normal variant in up to 4.8% of infants.¹ Occult spinal dysraphism (OSD) is unlikely. Spinal ultrasound in the absence of associated risk factors has low diagnostic yield and is not routinely indicated.^{2,3} However, certain sacral dimples and pits are more concerning and do require further investigation.

Simple vs Complex Sacral Dimples or Pits

Simple and complex sacral dimples or pits can be differentiated by their size, position, cutaneous stigmata and associated clinical findings (table 1).^{1,4,5}

Table 1: Features of Simple and Complex Sacral Dimples or Pits

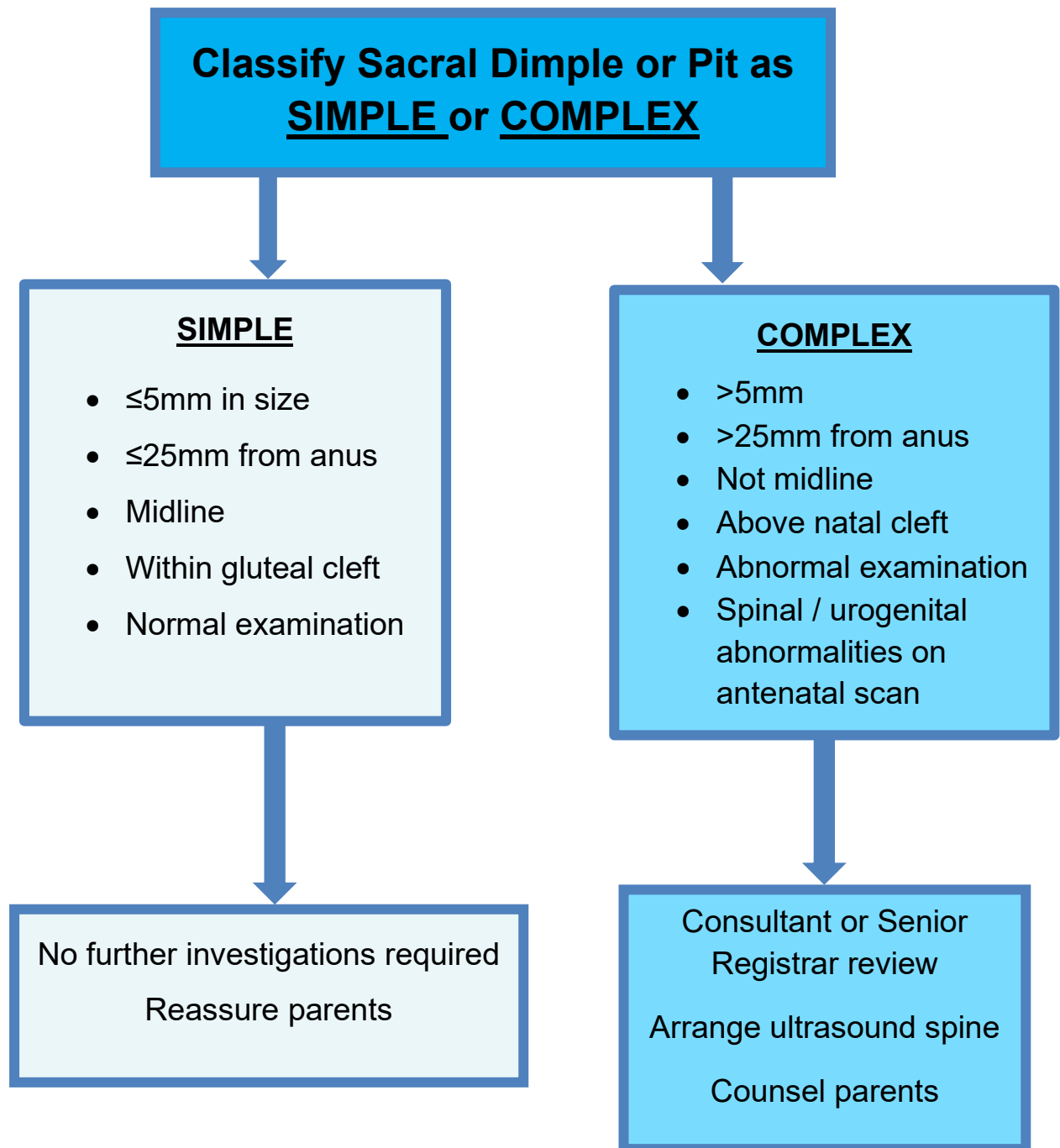
	Simple	Complex
Size	≤5mm	>5mm
Position	Midline Within gluteal cleft ≤25mm from anus	Not midline Above gluteal cleft >25mm from anus
Cutaneous abnormalities	None	Haemangiomas Hypertrichosis Caudal appendage Deviated gluteal fold
Associated clinical findings	None	Neurological deficit Neurogenic bladder and/or bowel dysfunction Orthopaedic abnormalities such as foot deformities or scoliosis Other congenital malformations including VACTERL ^α , OEIS ^β and anorectal malformations
Antenatal ultrasound	Normal	Abnormalities of spine / urogenital system

VACTERL^α: Vertebral defects, anal atresia, cardiac defects, tracheo-esophageal fistula, renal anomalies and limb abnormalities; **OEIS^β:** Omphalocele, exstrophy of the cloaca, imperforate anus and spinal defectsx

Investigation

Simple sacral dimples require no further investigation whereas complex ones do. An approach to ultrasound investigation of sacral dimples is presented in [figure 1](#). Cases in which the ultrasound findings are either equivocal or confirm spinal dysraphism may require an MRI of the spine and referral to the spinal rehabilitation clinic. Imaging studies can be done as an inpatient or an outpatient in order not to prolong hospital stays. Results of outpatient studies should be followed up at the senior registrar follow up clinic or by the patient's GP.

Figure 1: Spinal Ultrasound Investigation of a Sacral Dimple or Pit in a Neonate




Related CAHS internal policies, procedures and guidelines

[Neonatology Guidelines](#)

References and related external legislation, policies, and guidelines

1. Albert GW. Spine ultrasounds should not be routinely performed for patients with simple sacral pits. *Acta Paediatr.* 2016;105:890-894.
2. Gajagowni S, Altes T, Vachharajani AJ. Diagnostic Utility of Spinal Ultrasounds in Neonates. *Am J Perinatol.* 2023 Jan 16. doi: 10.1055/a-2000-6232. Epub ahead of print. PMID: 36528022.
3. McGovern M, Mulligan S, Carney O, Wall D, Moylett E. Ultrasound investigation of sacral dimples and other stigmata of spinal dysraphism. *Arch Dis Child.* 2013 Oct;98(10):784-6. doi: 10.1136/archdischild-2012-303564. Epub 2013 Aug 1. PMID: 23908189.
4. Kucera JN, Coley I, O'Hara S, et al. The simple sacral dimple: diagnostic yield of ultrasound in neonates. *Pediatr Radiol.* 2015;45:211-216.
5. Seregini F, Weatherby T, Beardsall K. Do all newborns with an isolated sacrococcygeal dimple require investigation for spinal dysraphism? *Arch Dis Child* 2019;104(8):816-818.

This document can be made available in alternative formats on request.

Document Owner:	Neonatology		
Reviewer / Team:	Neonatal Coordinating Group		
Date First Issued:	October 2014	Last Reviewed:	August 2023
Amendment Dates:		Next Review Date:	26th September 2026
Approved by:	Neonatal Coordinating Group	Date:	26 th September 2023
Endorsed by:	Neonatal Coordinating Group	Date:	
Standards Applicable:	NSQHS Standards:  Child Safe Standards: 1,10		

Printed or personally saved electronic copies of this document are considered uncontrolled



Healthy kids, healthy communities

Compassion

Excellence

Collaboration

Accountability

Equity

Respect

Neonatology | Community Health | Mental Health | Perth Children's Hospital