



GUIDELINE

Subgaleal Haemorrhage (SGH) Detection and Management in the Newborn

Scope (Staff):	Nursing and Medical Staff
Scope (Area):	NICU KEMH, NICU PCH, NETS WA

Child Safe Organisation Statement of Commitment

CAHS commits to being a child safe organisation by applying the National Principles for Child Safe Organisations. This is a commitment to a strong culture supported by robust policies and procedures to reduce the likelihood of harm to children and young people.

This document should be read in conjunction with this [disclaimer](#)

Contents

Aim 2

Risk 2

Background 2

Risk Factors 3

Recognition of SGH 3

Differential Diagnosis 4

Initial Actions: Delivery Suite and Postnatal Wards 4

 Level 1 Surveillance 4

 Level 2 Surveillance 4

 Level 3 Surveillance 5

 Immediate Investigations 5

Action in the Neonatal Nursery 5

Implications for Transport 6

Appendix 1: Subgaleal Haemorrhage Management Checklist 9

Aim

Subgaleal Haemorrhage (SGH) is an accumulation of blood in the loose connective tissue of the subgaleal space. This guideline outlines the diagnosis and management of the condition

Risk

Most catastrophic complication of instrumental delivery and, while rare, is associated with significant morbidity and mortality. Early recognition with a low threshold of suspicion is essential to initiate timely and effective management.

Background

- Naegele first described SGH in 1819.
- SGH can occur following normal birth, forceps delivery or caesarean section, most frequently follows vacuum assisted birth. The incidence has been estimated approximately as 1 in 2500 spontaneous vaginal deliveries without the use of vacuum or forceps, and a 10-fold increase is reported with the use of forceps. SGH is associated with 12-25% mortality due to potential of hypovolemic shock with 20-40% neonatal blood volume shifting into subgaleal space.

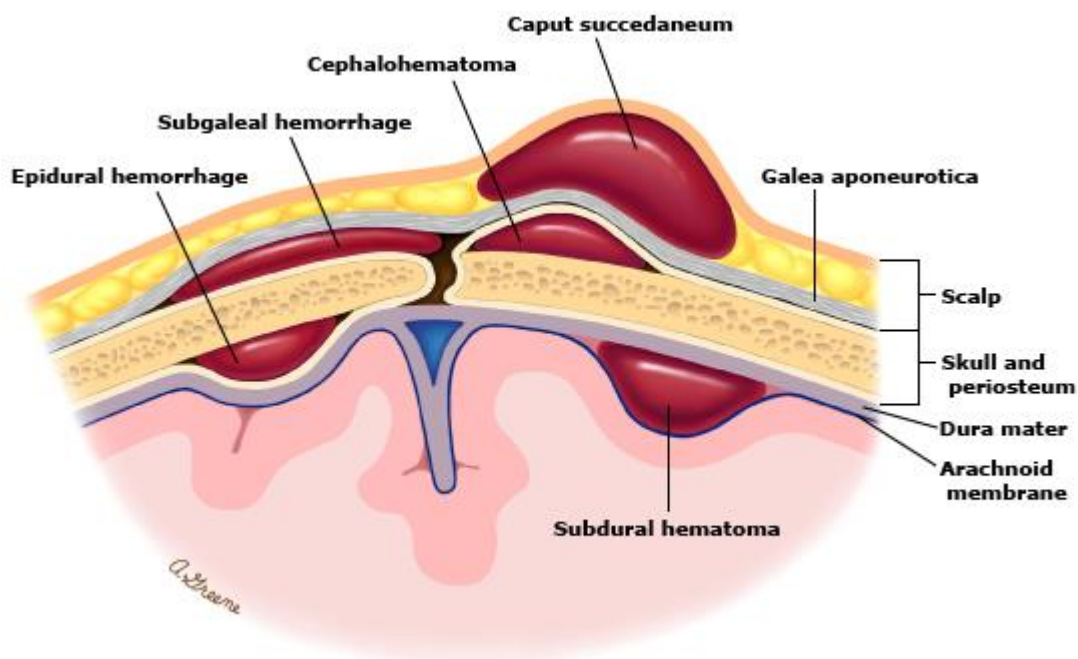


Figure 1: Extracranial haemorrhage in a newborn

Risk Factors

Vacuum extraction

SGH is often preceded by a difficult vacuum extraction with either incorrect positioning of the cup, prolonged extraction time (>20 minutes), >3 pulls or >2 cup detachments or failed vacuum extraction. Boo and colleagues also showed that nulliparity (adjusted OR 4.0), 5 minute Apgar score < 8, (OR 5.0), cup marks on the sagittal suture (OR 4.4), leading edge of cup < 3cm from anterior fontanelle (OR 6.0) or failed vacuum extraction (OR 16.4) were significant risk factors for SGH.

Other Risk Factors

Maternal factors: PROM >12 hours, maternal exhaustion and prolonged second stage, previous high or mid cavity forceps delivery.

Neonatal factors: Macrosomia, neonatal coagulopathy (Vitamin K deficiency, Factor VIII deficiency, Factor IX deficiency), low birthweight, male sex (2:1 to 8:1), low Apgar scores (< 8 at 5 minutes), need for resuscitation at birth and cord blood acidosis, fetal malpresentation.

Pathophysiology

Tractional and rotational forces with the use of vacuum extraction can result in rupture of veins and haemorrhage into different layers of the scalp. Most significantly, SGH may result from rupture of **emissary veins** into the subgaleal space. May (62-72% cases of SGH) may be associated with perinatal hypoxia.

Recognition of SGH

Local Signs

- **Early recognition is crucial for survival.** Combination of inspection and palpation to confirm SGH.
- Diffuse, fluctuant swelling of head which may shift with movement. Palpation of the scalp has been described as a **leather pouch filled with fluid**.
- As the haemorrhage extends, elevation and displacement of the ear lobes and peri orbital oedema (puffy eyelids) can be observed.
- Irritability and pain on handling will be noted.
- Days later bruising appears behind the ears and on the eyelids.

Systemic Signs

- Signs consistent with **hypovolemic shock:** tachycardia, tachypnoea, dropping haematocrit on blood gases, increasing lactates or worsening acidosis, poor activity, pallor, hypotension and acidosis. Neurological dysfunction and seizures are a late sign. Ischemic end organ damage to liver or kidneys can manifest as worsening liver and renal function and this is a poor prognostic indicator.

Subgaleal Haemorrhage (SGH) Detection and Management in the Newborn

- 6% of SGH cases are asymptomatic, 15-20% are mild, 40-50% are moderate and 25-33% are severe. Profound shock can occur rapidly with blood loss.

Differential Diagnosis (refer to Figure 1)

- **Cephalhaematoma:** well demarcated and does not cross suture lines. **SGH crosses suture lines.**
- **Caput succedaneum:** An oedematous collection of serosanguinous fluid in the subcutaneous scalp layer. A caput **has distinct borders, doesn't enlarge** and is **not fluctuant**. It is located where the vacuum was positioned, usually at the presenting part of the scalp. It typically resolves within 12-18 hours and there are no complications beyond a circular area of bruising.
- **Chignon (artificial caput succedaneum):** A collection of interstitial fluid and small haemorrhages that occur under the vacuum cap. It may cross suture lines, is most obvious after immediate removal of the cap and is firm in consistency. It starts resolving within an hour of birth and should completely resolve within 18 hours. There is no long term significance for the newborn.

Initial Action: In the Delivery Suite and Postnatal Wards

Administer intramuscular vitamin K as soon as possible.

RANZCOG recommendations

Level 1 surveillance

Minimum for all infants delivered by instrumental delivery

- Baseline observations (activity, colour, heart rate, respiratory rate, blood pressure and head circumference) at one hour.
- Avoid hats/ bonnets (or remove frequently) to note head shape (increase in head circumference by 1cm may suggest 40mL blood seepage into subgaleal space).
- Clinical concerns (to increase observation frequency/ escalate to Level 2 surveillance).

Level 2 surveillance

Indicated: if vacuum extraction time total >20 minutes and/or > 3 pulls and/or > 2 cup detachments, clinical concerns from level 1 surveillance, at clinician's request

- Take cord blood (acid base status, pH, and lactate).
- Hematocrit/ FBP and platelet count.
- Hourly observations for first 2hrs, then 2hrly for next 6hrs. Can extend observations for at least first 12-24 hours, consider saturation monitoring.
- Document activity, colour, heart rate, respiratory rate, blood pressure, head size and shape, location and nature of swelling.

Subgaleal Haemorrhage (SGH) Detection and Management in the Newborn

Level 3 surveillance

Indications: clinical suspicion of SGH immediately following delivery, clinical concerns on Level 2 surveillance

- Urgent review by paediatric senior registrar or consultant paediatrician. If SGH confirmed, consider admission to special care nursery.

Immediate Investigations:

- Full blood picture and Coagulation profile: On admission and repeated at clinical team's discretion. Up to 81% of neonates with SGH may develop coagulopathy.
- Group & blood x match (notify blood bank). Refer to Transfusion Medicine Policy: [Major Haemorrhage and Urgent Transfusion Requests](#) and [Neonatal Critical Bleeding Protocol](#).
- Venous/capillary gas including lactate and base excess, electrolytes (2-4 hourly).
- Maintain blood glucose level > 2.6 mmol/L.

Actions in the Neonatal Nursery

The basis of effective management is aggressive resuscitation to restore blood volume, provide circulatory support, correction of acidosis and coagulopathy.

See [Neonatal Critical Bleeding Protocol](#)

Above investigations to be carried out after insertion of a peripheral intravenous access, which should be left indwelling for 12 hours if baby remaining in nursery.

Ongoing Monitoring

- Continuously monitor heart rate, respiration, oxygen saturation and blood pressure (non-invasively if no arterial line) at least for the first 24 hours.
- Continue to assess capillary refill and peripheral perfusion.
- Regularly observe and palpate scalp swelling to assess for continuing blood loss, change in head shape or head circumference.
 - Measure head circumference hourly for the first 6-8 hours of life, (refer to criteria for determining severity of SGH from Chadwick et al: Table below), change in colour, displacement of ears.

	Head Size	Jaundice	Hypovolemia
Mild	Increase of <1cm	Absent	None
Moderate	Increase of 1-3 cm	Present	Mild: plasma expander only
Severe	Increase of >3cm	Present	Blood and plasma expander, may need multiple transfusions

Subgaleal Haemorrhage (SGH) Detection and Management in the Newborn

- Volume replacement: 20 mL/kg of normal saline, if severe hypovolemia, request for urgent O negative blood and FFP. Refer to [Neonatal Critical Bleeding Protocol](#).
- Monitor urine output.
- Repeat FBC and coagulations studies, (4-6 hours after initial assessment).
- If coagulation studies are abnormal then correct with 20mLs/kg of Fresh Frozen Plasma. Consider giving Cryoprecipitate 5mLs/kg, if there is continued bleeding or the fibrinogen level are less than 1.5 g/l. Discuss with on call haematologist about the need for use of recombinant factor VIIa.
- If thrombocytopenic, consider platelet transfusion (if platelet count<50).
- Inotropes, vasopressors and multiple packed red cell transfusions may be required for severe cases of shock.
- Ongoing assessment for jaundice.

Recognition of Hypovolaemia

Pointers to significant volume loss include:

- A high or increasing heart rate (> 160 bpm), low or falling haemoglobin or haematocrit, poor peripheral perfusion with slow capillary refill (>3 seconds), low or falling blood pressure (MBP < 40 mmHg in a term baby), presence of or worsening of a metabolic acidosis.
- Consideration of a functional bedside echocardiography (by the attending neonatologist) can be useful in assessment of volume status. Small systemic veins and low ventricular filling volumes can be pointers to hypovolaemia.

Consider Elective Intubation and Ventilation for Worsening Shock.

Look for concomitant injuries:

- Hypoxic ischaemic encephalopathy occurs in 62-72% of SGH. Brain trauma resulting in cerebral oedema and/or intracranial hemorrhage occurs in 33-40%.
- Less common: subdural hematoma, dural tear with herniation, superior sagittal sinus rupture, pseudomeningocele and encephalocele, and subconjunctival and retinal haemorrhage. Elevated intracranial pressure (ICP) from the SGH mass effect is reported. Skull fractures may be associated. Once stabilized, consider neuroimaging (cranial ultrasound or MRI).

Communication with Parents

- Keep parents informed and obtain consent for the administration of blood products.
- Reassure and keep communication open and honest.

Implications for Transport

- Assess and stabilize respiratory status.
- Assess head and skull for abrasion, ecchymosis, and swelling.
- Measure head circumference.
- Obtain laboratory studies: blood gas, type and cross, FBP, and coagulation studies.
- Establish intravenous access, umbilical lines when appropriate.
- Identify availability of blood products.
- Communicate status and plan of care with parents.
- Communicate status with transport team and/or referral facility/physician.
- Continue frequent assessment of vital signs, respiratory status, head examination, and laboratory studies including blood gases, haematocrit, base excess and electrolytes.

Related CAHS internal policies, procedures and guidelines

Transfusion Medicine: [Major Haemorrhage and Urgent Transfusion Requests](#)
Neonatal Clinical Guideline: [Critical Bleeding Protocol](#)


References and related external legislation, policies, and guidelines

1. Lee SJ, Kim JK, Kim SJ. The clinical characteristics and prognosis of subgaleal hemorrhage in newborn. *Korean J Pediatr.* 2018 Dec; 61(12):387-391.
2. Assad M, Spaight M, Sink D, Martin J. Early recognition and management of fetal head trauma with massive subgaleal haemorrhage. *J Neonatal Perinatal Med.* 2018; 11(4):433-438.
3. Boo NY, Foong KW, Mahsy ZA, Yong SC, Jaafar R. Risk factors associated with subaponeurotic haemorrhage in full term infants exposed to vacuum extraction. *Br J Obstet Gynaecol,* 2005: 112; 1516-21
4. State Coroner South Australia. Finding of Inquest 36/2009 (1762/2006, 0493/2007), 2010.
5. Krispin E, Aviram A, Salman L, Chen R, Wiznitzer A, Gabbay-Benziv R. Cup detachment during vacuum-assisted vaginal delivery and birth outcome. *Arch Gynecol Obstet.* 2017 Nov; 296(5):877-883.
6. Struass T, Kenet G, Schushan-Eisen I, Mazkereth R, Kuint J. Rescue recombinant activated factor VII for neonatal subgaleal hemorrhage. *Isr Med Assoc J.* 2009; 11: 639–40.
7. Shah NA, Wusthoff CJ. Intracranial Hemorrhage in the Neonate. *Neonatal Netw.* 2016; 35(2):67-71.

Subgaleal Haemorrhage (SGH) Detection and Management in the Newborn

8. Schierholz E, Walker SR. Responding to traumatic birth: subgaleal hemorrhage, assessment, and management during transport. *Adv Neonatal Care*. 2014 Oct 14 Suppl 5:S11-5.
9. Michael J Colditz, Melissa M Lai, David W Cartwright and Paul B Colditz Subgaleal haemorrhage in the newborn: A call for early diagnosis and aggressive management. *Journal of Paediatrics and Child Health* 51 (2015) 140–146
10. Royal Australian and New Zealand College of Obstetricians and Gynaecologists. Prevention, Detection and Management of Subgaleal Haemorrhage in the Newborn Royal Australian and New Zealand College of Obstetricians and Gynaecologists. 2009. Available from: <http://www.ranzcog.edu.au/college-statements-guidelines.html> [accessed July 2019; noted under review].

This document can be made available in alternative formats on request.

Document Owner:	Neonatology		
Reviewer / Team:	Neonatal Coordinating Group		
Date First Issued:	December 2015	Last Reviewed:	11 th July 2021
Amendment Dates:		Next Review Date:	11 th July 2024
Approved by:	Neonatal Coordinating Group	Date:	27 th July 2021
Endorsed by:	Neonatal Coordinating Group	Date:	
Standards Applicable:	NSQHS Standards:  Child Safe Standards: 1,10		

Printed or personally saved electronic copies of this document are considered uncontrolled



Healthy kids, healthy communities

Compassion

Excellence

Collaboration

Accountability

Equity

Respect

Neonatology | Community Health | Mental Health | Perth Children's Hospital

Appendix 1: Subgaleal Haemorrhage Management Checklist

Vital Signs	Hourly for 6 hours then <ul style="list-style-type: none"> • 2 hourly for 24 hours
Blood Pressure	15 minutely for 4 hours or
	15 minutely for first hour, then <ul style="list-style-type: none"> • hourly for 4 hours, then • 4 hourly thereafter
Head Circumference	Hourly for at least 8 hours, then <ul style="list-style-type: none"> • 2 hourly for 8 hours, then if stable • 4 hourly for 8 hours
Investigations	
Initial	FBE, coagulation profile, blood gas (lactate), blood group and cross match
Subsequent testing	Hb/ blood gas 2-4 hourly Liver function test SBR/ TCB if >36 weeks
	If unstable <ul style="list-style-type: none"> • FBE 4-6 hourly (for Hb and PLT monitoring) • Coagulation profile 4-6 hourly
Red Flags	
<ul style="list-style-type: none"> • INR >2 • Trend of dropping Hb • Rising lactate • Worsening base deficit • Worsening tachycardia 	